

Automatic Detection of Exudates in Retinal Images

Nidhal K. El Abbadi¹ Enas Hamood Al- Saadi²
¹ University of Kufa, Najaf, Iraq

² University of Babylon, Babylon, Iraq

Abstract

Diabetic retinopathy is a major cause of blindness. Earliest signs of diabetic retinopathy are damage of blood vessels in the eye and then formation of lesions in the retina. This paper presents an automated method for detection of bright lesions (exudates) in retinal images. New methods are developed to localize and isolate the optic disk and detect the exudates. A novel algorithm is presented to localize the optic disk and treat the confusion due to similarity between exudates and optic disk. The algorithm use specific color channels and some of image features to separate exudates from physiological features in digital fundus images. The algorithm is tested on many images from published database and gives excellent and promise results.

Keywords: retina, optic disk, exudates, diabetic, retinopathy.

1. Introduction

Diabetic retinopathy (DR), the major cause of poor vision, is an eye disease that is associated with long-standing diabetes. If the disease is detected in its early stages, treatment can slow down the progression of DR. However, this is not an easy task, as DR often has no early warning signs. Earliest signs of DR are damages of the blood vessels and then formation of lesions. Lesions such as exudates are normally detected and graded manually by clinicians in time consuming and it is susceptible to observer error.

Diabetic retinopathy results from the leakage of small vessels in the retina correlated to a prolonged period of hyperglycemia. In the early stages of the disease, known as non-proliferative retinopathy, there may be hemorrhages due to bleeding of the capillaries or exudates resulting from protein deposits in the retina. There is usually no vision loss unless there is a build-up of fluid in the center of the eye. As the disease progresses, new abnormal vessels grow in the retina, known as revascularization. This stage of the disease is called proliferative retinopathy and may cause severe visual problems.

Exudates are common abnormalities in the retina of diabetic patients. Exudates are bright lipids leaked

from a blood vessel. The leaked fluid tends to stay close to the lesion, giving a generally well-defined edge suitable for computer analysis. Figure (1) gives an example of exudates, which show up as small, light yellow regions.

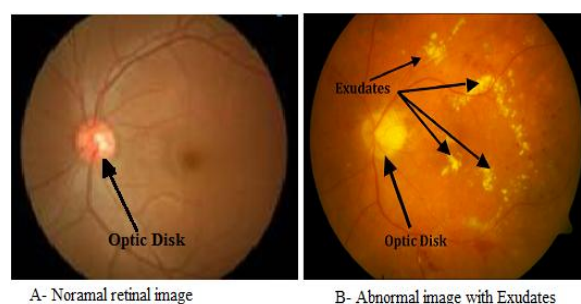


Fig 1: Normal and abnormal retinal image

This paper focuses mainly on exudates because it provides information about early diabetic retinopathy. The chief cause of exudates is leaking of proteins and lipids from the bloodstream into the retina through damaged blood vessels [9]. In retinal images, exudate exhibits as hard white or yellowish localized regions with varying sizes, shapes and locations. Generally, they materialize near the leaking capillaries within the retina [10]. The hard exudates are formations of lipid that are leaking from these weakened blood vessels. This kind of the retinopathy is termed as non-proliferative diabetic retinopathy.

Optic disk is also bright yellow region which have similar appearance of exudates. The optic disk, which can be seen in Figure 1, is also a light yellow region. Therefore, before searching for exudates based on their yellow color, an algorithm is developed for automatic detection of the optic disk to eliminate this physiologically valid, yet it has similar structure. The localization of the optic disk as the identification of the center of disk is either by specifying the center of the optic disk or placing a mask within a particular region of the retina. Segmentation of the optic disk usually refers to the subsequent task of determining the contour of the disk. Localization and segmentation of the optic disk are important tasks in retinal image analysis.

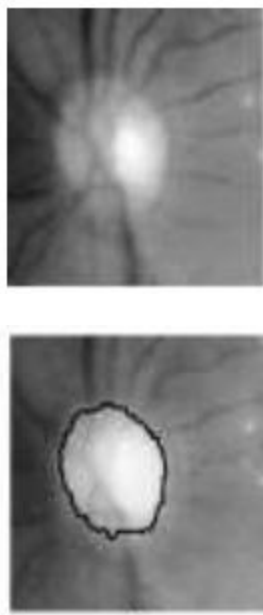


Fig 2: Localization and segmentation of the optic disk

Detection of exudates by computer could offer fast and precise diagnosis to specialist inspection. Also it assists the clinician to take timely the right treatment decision.

2. Related work

In 1999 Sinthanayothin *et al.* detected the optic disk by localized and segmented the area in the image which has high grey level variation, if there is no or only few pathologies such as exudates which are bright this approach work well. Walter and Klein [13] in 2001 detected position of the optic disk, and then extracts the contours of the optic disk by the means of the watershed transform. In 2003 Hoover and Goldbaum [2] used fuzzy voting mechanism to detect the location of the optic disk. The optic disk is the location where most elements overlap. Also in 2004 Foracchia *et al.* [10] presented a method to detect the location of the optic disk based on the global orientation of the vasculature. A geometrical model of the average vessel orientation on the retina with respect to the optic disk location was fitted to the image. Li *et al.* in 2004 [9] proposed a method based on dividing the image into 64 sub-images followed by applying a combination of region growing and edge detection to detect exudates. The fuzzy C-means clustering was used by Sopharak *et al.*, in 2009 [3] for the segmentation of exudates followed by classification using a morphological technique. Garcia *et al.* in 2009 [11] used a combination of local and global threshold to segment exudates followed by

investigating three neural network classifiers to classify exudates. While Sanchez *et al.* in 2009 [5] suggested a method based on mixture models to separate exudates from background followed by edge detection technique to distinguish hard exudates from soft exudates.

In 2010 Singh and Chandra presented a method to automated early detection of diabetic retinopathy using image analysis techniques. The automated diabetic retinopathy diagnosis system was thus used to various lesions of the retina i.e. exudates, micro-aneurysms, hemorrhages, their count size and location to assess the severity of the disease, so that the patient can be diagnosed early and referred to the specialist well in advance for further intervention.

Reza *et al.*, in 2010 [4] presented new method to detects the bright objects such as optic disk and exudates based on marker-controlled watershed segmentation and using of average filtering and contrast adjustment. A method based on mathematical morphology for exudates detection has been proposed by Welfer *et al.* in 2010 [7].

3. Methodology

A proposed algorithm was written for automatically detecting optic disk and exudates in the retinal images. The algorithm was developed based on fundus images. The type of DR presented in the images was exudates.

The goal of the paper is detection of the non-proliferative stage of DR which is exudates so that the disease can be managed appropriately to decrease the chances of vision impairment.

The representation of an image in RGB color space allows to studying separately the different channels of the spectral response. The three channels are (red, green and blue) each of which has intensity value ranging between 0 and 255.

Exudates detection faces some of problems that effect on the efficiency of any detecting algorithm. One of the major problems faces exudates detection is the color similarity between optic disc and exudates. Other thing is the recognition of false exudates.

3.1 Preprocessing

The first step in this work is to element the optic disc. Fundus image is an RGB color image, in general RGB images consist of three channels (red, green, and blue), this feature will investigate in this paper localization of the optic disc. This can be

accomplished by separation the retina of image to three channels and using only two of them (red and green channels), the blue channel is characterized by low contrast and does not contain much information. The vessels are visible in the red channel but this channel usually contains too much noise or it is simply saturated, since most of the features emit a signal in the red channel. While the green component of the color retina image gives the best result in the contrast of blood vessels (darker blood vessels on a bright background). Therefore, the green channel of the image is used in the automated analysis of fundus images.

Optic disk is bright region (alight yellow region) which has similar appearance of exudates Fig (1). Therefore, before searching for exudates based on their yellow color, an algorithm is developed for automatic detection of the optic disk. The yellow color corresponds to high intensity in the green channel, and typically the optic disk contains the majority of the highest green intensities on a given image.

First step to element the optic disk is determination of the center of optic disk which is the lighter and brightest part in retina image. This property investing to determine the center of optic disk and localization of the optic disk, this will be achieved by compute red channel (R) and green channel (G) from the original RGB color retinal image then compute the ratio between red and green channel (R/G) to obtain all light and bright regions in the image.

For each pixel we calculate (D), where

$$D = R / G$$

In order to get all the light and bright regions in image we have to determine the max value of (D). The experiment proved that the pixels with intensity value (x) represent the center of optic disk (almost few numbers of pixels have this property), where

$$\text{Max}(D) \leq x \leq 255$$

After determination of the center we have to calculate the radius of optic disk, this will be done by exploring and counting the intensity of each pixel from the center of optic disk (in four direction two horizontally and the other two vertically) toward the optic disk edge (optic disk edge is the line separates between two regions different in colors intensity).

Determination of the four radiuses in four directions gets the correct radius. When we determine the center and radius we cover the optic disk with black circle has the same optic disk radius fig 3.

Note that this algorithm is applicable to both left and right eyes.

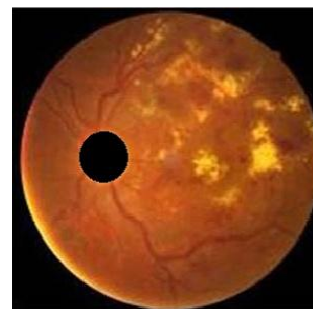

Fig 3: retina image where the optic disk covered with black circle

3.2 Exudates Detection

The next step is to detect all the exudates in the retinal image; this will be achieved by using the green channel of the retina image fig (4).

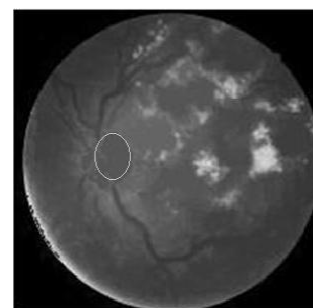


Fig 4: green channel of retina image.

The intensity plays important role in detection of exudates, in practices the “light” part in retina image represented with high numbers in terms of intensities, each pixel in image has intensity value ranging from 0 (darkest pixel), and 255 (light pixel). The regions with high and low intensities in image may have very important features because it marked as image objects.

In an image of several objects, points of high intensity could represent the tops of the objects; these maxima can be used to identify objects in an image. An image can has multiple regional maxima in term of intensity and texture but only a single global maxima which has intensities larger than or equal to threshold (110) (the band of exudates) and has similar determined texture. This process converts the image to binary image by changing each pixel equal or greater than threshold to white color with value 1, while the other pixel will change to black color with value 0.

This process will convert image to binary image where the white pixels represent the exudates and all the other image details are changed to background as black color.

3.3 Separation of True from False Exudates

Exudates in image are two types: true exudates and false exudates (which is any spot looks like the exudates, such as light spots).

All the components in the binary image will be labeled by using image label algorithm, by scan all image pixels, assigning preliminary labels to nonzero pixels and recording label equivalences in a union-find table. Then resolve the equivalence classes using the union-find algorithm (The Union-Find algorithm is used for maintaining a number of non-overlapping sets from a finite universe of elements). Finally re-label the pixels based on the resolved equivalence classes.

Final step is computing texture for all labeled regions in the retinal image. An important approach for describing a region is achieved to quantify its texture content. In this paper method used for computing texture based on statistical measure, texture analysis is based on statistical properties of the intensity histogram. One class of such measure is based on statistical moments; from this method we suggest 6 texture measures for each region which are (average intensity (mean), average contrast (standard deviation), smoothness, third moment, uniformity and entropy).

$$\text{Mean (m)} = \sum_{i=0}^{L-1} z_i p(z_i)$$

$$\text{Standard deviation} = \sigma = \sqrt{\mu_2(z)}$$

$$\text{Smoothness} = R = 1 - 1/(1 + \sigma^2)$$

$$\text{Third moment} = \mu_3 = \sum_{i=0}^{L-1} (z_i - m)^3 p(z_i)$$

$$\text{Uniformity} = U = \sum_{i=0}^{L-1} p^2(z_i)$$

$$\text{Entropy} = - \sum_{i=0}^{L-1} p(z_i) \log_2 p(z_i)$$

Where z_i is a variable indicating intensity at location (i), $p(z)$ is the histogram of the intensity levels in a region, L is the number of possible intensity levels.

The entropy of the false exudates is higher than the other (true exudates), this also is true for the contrast, and average intensity in this case. On the other hand this region is the least smooth and the least uniform as revealed by the values of smoothness and the uniformity measure.

Measurements of the texture of each region will be highly distinguished between the true and false exudates as shown in table (1).

False exudates removed by re-labeled it using union-find algorithm, edge detection, and determined its size prior to segment it. All the false exudates are eliminated according to its size and location.

The remained in image is only the true exudates. And the output is number of exudates and number of pixels represent its.

Table 1: Texture Measures for retinal image

Texture	True Exudates	False Exudates
Average	5.6777	1.8016
Contrast	37.6241	21.3582
Smoothness	0.0213	0.0070
Third moment	5.3041	1.7636
Uniformity	0.9565	0.9860
Entropy	0.1540	0.0606

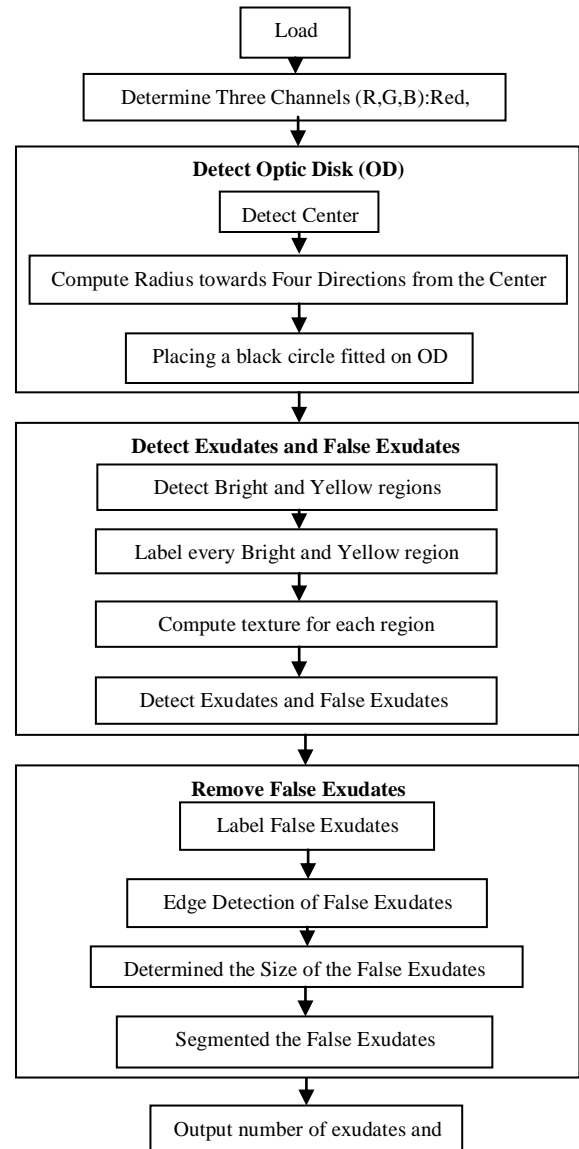


Fig 5: Algorithm for detection of exudates

4. Conclusion

Automatic methods for screening exudates have been developed based on image processing methods that utilize color, intensity gradients, and image textures in fundus photographs. Many images from a standard database were used to test the methods.

From table (1), we conclude that the texture measurements of all the true exudates are similar, but they different in large range from the texture measurements of the false exudates.

This paper introduced new methods to element the optic disk, and removes the main part that makes confusion with exudates.

The result of this algorithm very promising and detects all the exudates in the image precisely.

References

[1] Akara et al, "Fine Exudate Detection using Morphological Reconstruction Enhancement", International Journal Of Applied Biomedical Engineering, Vol. 1, No. 1, 2010.

[2] A. Hoover and M. Goldbaum, "Locating the optic nerve in a retinal image using the fuzzy convergence of the blood vessels," IEEE Trans. Med. Imag., Vol. 22, No. 8, pp. 951–958, Aug. 2003.

[3] A. Sopharak and B. Uyyanonvara, "Automatic Exudates Detection from Non-dilated Diabetic Retinopathy Retinal Images Using Fuzzy C-means Clustering," *Sensor*, Vol. 9, No. 3, pp. 2148-2161, 2009.

[4] A. W. Reza, C. Eswaran and K. Dimiyati, "Diagnosis of Diabetic Retinopathy: Automatic Extraction of Optic Disc and Exudates from Retinal Images Using Marker-controlled Watershed Transformation," *Springer, J Med. Syst.*, online Jan. 2010.

[5] C. I. Sanchez, M. Garcia, A. Mayo, M. Lopez and R. Hornero, "Retinal image analysis based on mixture models to detect hard exudates," *Medical Image Analysis*, Vol. 13, pp. 650-658, 2009.

[6] C. Sinthanayothin, J. F. Boyce, H. L. Cook, and T. H. Williamson, "Automated localization of the optic disc, fovea and retinal blood vessels from digital color fundus images," *Br. J. Ophthalmol.*, Vol. 83, pp. 231–238, Aug. 1999.

[7] D. Welfer, J Scharcanski and D. R. Marinho, "A coarse-to-fine strategy for automatically detecting exudates in color eye fundus images," *Computerized*

Medical Imaging and Graphics, Vol. 34, pp. 228-235, 2010.

[8] F. Mendels, C. Heneghan, and J.-P. Thiran, "Identification of the optic disk boundary in retinal images using active contours," in Proc. Irish Machine Vision Image Processing Conf. (IMVIP'99), pp. 103–115, Sept. 1999.

[9] H. Li and O. Chutatape, "Automated feature extraction in color retinal images by a model based approach," *IEEE Trans. on Medical Engineering*, Vol. 51, pp. 246-254, 2004.

[10] M. Foracchia, E. Grisan, and A. Ruggeri, "Detection of optic disk in retinal images by means of a geometrical model of vessel structure," *IEEE Trans. Med. Imag.*, Vol. 23, No. 10, pp. 1189–1195, Oct. 2004.

[11] M. Garcia, C. I. Sanchez, M. I. Lopez, D. Abasolo and R. Hornero, "Neural network based detección of hard exudates in retinal images," *Computer Methods and Programs in Biomedicine*, Vol. 93, pp. 9-19, 2009.

[12] S. Neera, and R. Chandra, "Automated early detection of diabetic retinopathy using image analysis techniques", International Journal of Computer Applications (0975 – 8887), Vol. 8, No.2, October 2010.

[13] Thomas Walter and Jean-Claude Klein, "Segmentation of Color Fundus Images of the Human Retina: Detection of the Optic Disc and the Vascular Tree Using Morphological Techniques", J. Crespo, V. Maojo, and F. Martin (Eds.): ISMDA 2001, LNCS 2199, pp. 282–287, 2001. @ Springer-Verlag Berlin Heidelberg 2001.



Nidhal El-Abbadi

Received BSc in chemical engineering, MSc, and PhD in computer science, worked in industry and many universities, he is general secretary of colleges of computing and informatics society in Iraq, Member of Editorial board of Journal of Computing and Applications, reviewer for a number of international journals, has many published papers and three published books (Programming with Pascal, C++ from beginning to OOP, Data structures in simple language), his research interests are in image processing, biomedical, and steganography, He's Associate Professor in Computer Science in the University of Kufa – Najaf, IRAQ.

Enas Hamood, received her BSc. in Computer science from Babylon University, Msc. in Computer science from Babylon University, currently she is PhD student in computer science department, college of science- Babylon University.

Work as a lecturer in college of education- Babylon University. She has 6 researches in computer science fields.